

Rotationplasty of the Knee

*Lizz van der Heijden, Jonneke Kuperus, Michiel van de Sande*

*Princess Máxima Center for Pediatric Oncology, Utrecht, the Netherlands*

---

PUBLISHED IN THE EDITED VOLUME

**Bone Tumors - Pathogenesis, Diagnosis, and Management**

Submitted: 20 November 2025 Reviewed: 25 November 2025 Published: 25 February 2026

van der Heijden L, Kuperus and Michiel van de Sande J. Rotationplasty of the Knee. Bone Tumors - Pathogenesis, Diagnosis, and Management. IntechOpen; 2026.

DOI: <http://dx.doi.org/10.5772/intechopen.1014143>

## Chapter

# Rotationplasty of the Knee

*Lizz van der Heijden, Jonneke Kuperus and  
Michiel van de Sande*

## Abstract

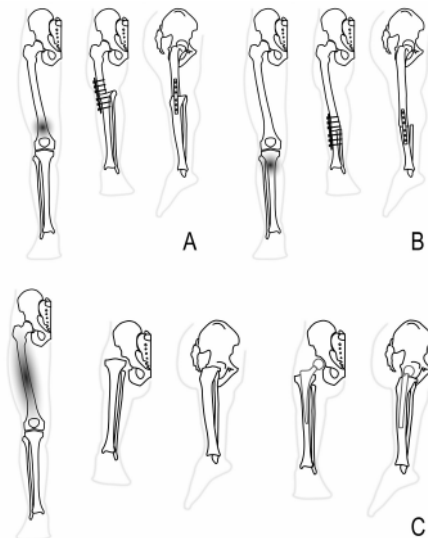
Rotationplasty is a biological limb-salvage procedure originally developed for tuberculosis and congenital femoral deficiency and later adopted in orthopedic oncology for malignant bone tumors around the knee. The technique involves a 180° rotation of the distal limb and fusion to the proximal femur, allowing the ankle joint to function as a neo-knee and enabling use of a below-knee prosthesis with highly efficient gait mechanics. Compared with transfemoral amputation or endoprosthetic reconstruction, rotationplasty offers important advantages, including durability during growth, a low revision burden, excellent energy efficiency, and high long-term patient satisfaction. Primary oncologic indications include high-grade malignant tumors of the distal femur (Winkelmann type A1), proximal tibia (A2), and selected cases requiring total femur resection (B3). Non-oncologic indications include severe congenital femoral deficiency. Absolute contraindications are loss of tibial nerve function, irreparable vascular compromise, and severe ankle stiffness, while psychosocial intolerance and limited survival prognosis are considered relative contraindications. Optimal outcomes depend on multidisciplinary preparation, including psychosocial counseling, growth prediction, and early prosthetic planning. Surgical technique emphasizes meticulous neurovascular preservation or reconstruction, perpendicular osteotomies, and controlled rotation guided by preoperative alignment markings. Fixation is most commonly achieved using locking plates, with adapted reconstructive strategies for total femur cases. Postoperative management includes vascular monitoring, early mobilization, and structured rehabilitation. Long-term results demonstrate excellent functional outcomes, high levels of physical activity, and superior gait efficiency compared with transfemoral amputation. When carefully selected and precisely executed, rotationplasty remains a durable and effective reconstructive option that preserves function and quality of life in young patients undergoing limb-sparing tumor surgery.

**Keywords:** rotationplasty, pediatric limb-salvage surgery, bone sarcoma, growth (prediction), functional outcomes

## 1. Introduction: Background and rationale

Rotationplasty was first described by Borggreve (1927) for severe bone loss caused by tuberculosis and was later popularized by Van Nes (1950) for congenital femoral deficiency (CFD). The rotationplasty (Borggreve–Van Nes procedure) gained oncologic use in the 1980s for treating osteosarcoma and Ewing sarcoma. In orthopedic oncology, rotationplasty is a biological limb-salvage technique that enables durable reconstruction following the resection of malignant bone tumors around the knee. Rotationplasty is performed especially in pediatric patients with bone tumors but may also be preferred over megaprotheses in low- and middle-income countries due to cost and availability.

In rotationplasty surgery, the ankle is repurposed as a functional “knee” by rotating the distal limb 180° and fusing it to the proximal femur (**Figure 1**). The leg can be fitted with a below-knee-amputation-type prosthetic leg, where the ankle functions as the new “knee” and the foot functions as the tibia. In this manner, ankle plantar flexion acts as “knee” extension and ankle dorsiflexion as “knee” flexion. Advantages, compared with above-knee amputation or megaprotheses, include biological reconstruction, durability across growth, lower revision burden, efficient gait, and high long-term patient satisfaction when psychosocial preparation is adequate [1–4].



**Figure 1.** Different types of rotationplasty about the knee. (a) Winkelman type A1 for distal femur tumors. (b) Winkelman type A2 for proximal tibia tumors. (c) Winkelman type B3A/B for total femur resection, replacing the femoral head with the tibia in a very young patient or with a femoral prosthesis.

## **2. Indications and patient selection**

### **2.1 Oncologic indications**

The primary indications for rotationplasty of the knee are high-grade malignant tumors of the distal femur (Winkelmann Type A1) or proximal tibia (Winkelmann Type A2), and, less frequently, for total femoral resections (Winkelmann Type B3) [1].

Relative indications for rotationplasty are large tumor extensions outside and inside the knee joint, requiring extra-articular resection, or more than 40% of growth remaining in young children. Rotationplasty is also considered when expandable prostheses would carry an unacceptably high revision risk during growth, or when infection or a poor soft-tissue envelope precludes megaprosthesis reconstruction [4].

Unlike megaprosthesis reconstruction or amputation, rotationplasty offers the following:

- Durable, growth-adapted biomechanics without the revision burden of expandable prostheses.
- Efficient gait mechanics, as ankle plantarflexion substitutes for knee extension.
- Lower long-term complication rates, with fewer re-operations compared to prosthetic reconstructions.
- High patient satisfaction and psychosocial adaptation occur when adequate preoperative counseling is provided.

Modern series with over 30 years of follow-up demonstrate sustained functional capacity, confirming its role as a definitive solution in young, active patients [5].

### **2.2 Non-oncologic indications**

Non-oncologic indications include CFD, especially severe proximal femoral focal deficiency (PFFD) [6], and, in selected cases, complex trauma or chronic osteoarticular infections resulting in severe lower limb bone loss [4]. Several variants of the rotationplasty techniques have been described for different types of PFFD by Paley but are not discussed in this chapter [6].

### **2.3 Contraindications**

Absolute contraindications include irreparable vascular compromise (i.e., long-standing arterial occlusion or extensive deep venous thrombosis [DVT]), loss of tibial nerve function, or severely restricted ankle motion (**Table 1**). Tumor involvement of the artery and vein is not necessarily a contraindication for rotationplasty, as they can be resected and anastomosed proximally for Winkelmann A1 and, to a lesser extent, in Winkelmann A2 rotationplasty. Ankle function should minimally range from plantigrade to 90 degrees plantar flexion.

---

Absolute contraindications

- Irreparable vascular compromise (arterial occlusion, extensive venous thrombosis).
- Loss of tibial nerve function, precluding ankle motor control.
- Ankle stiffness or degenerative change preventing effective neo-knee function.

---

Relative contraindications

- Peroneal nerve function loss after resection.
  - Severe psychosocial intolerance to cosmesis.
  - Poor systemic health, precluding long rehabilitation.
- 

**Table 1.**

*Overview of absolute and relative contraindications for rotationplasty.*

Relative contraindications include peroneal nerve function loss after resection, anticipated psychosocial distress, or very poor systemic therapy response and/or extensive pulmonary metastatic disease [4, 7, 8]. Peroneal nerve loss can sometimes be accepted in Winkelmann A2 rotationplasty, and to a lesser extent in Winkelmann A1 rotationplasty, if tibial nerve function, and thus the driving, extending motor unit of the ankle, remains intact. Rotationplasty is a life and limb-altering procedure with accompanying rehabilitation and acceptance, and poor survival prognosis can therefore be a relative contraindication.

### **3. Preparation**

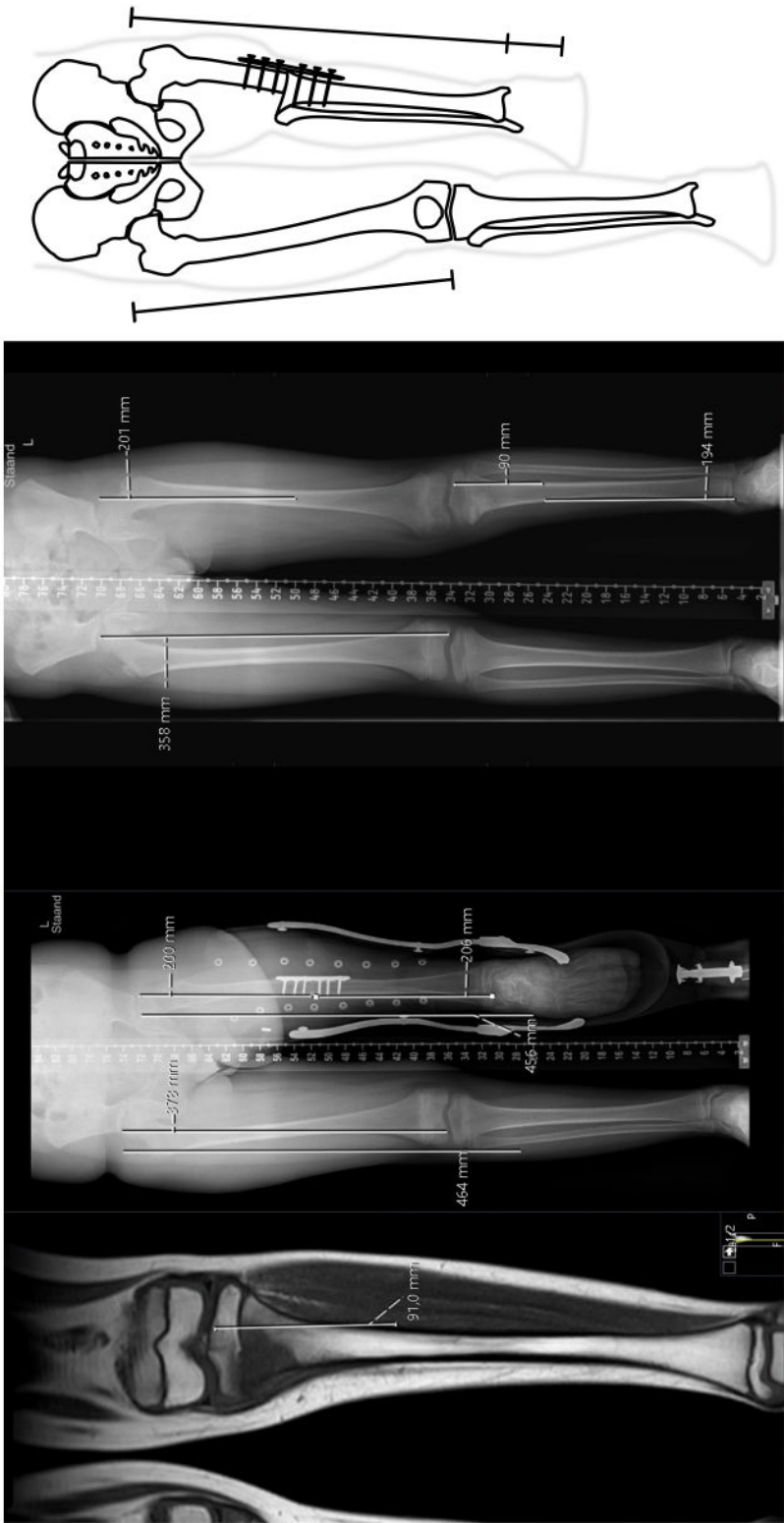
#### **3.1 Multidisciplinary preparation**

Optimal preparation includes preoperative counseling of patients and parents with illustrations, photos, and videos; psychosocial assessment; preoperative physiotherapy input; vascular imaging; and prosthetic planning. Preoperative peer support through meeting other patients and parents improves acceptance [1, 4].

#### **3.2 Growth calculations and leg-length prediction**

In children, predicting final leg length at the end of skeletal maturity is crucial (**Figure 2**). Anderson et al. (1963) quantified growth: ~70% of femoral growth arises from the distal femoral physis (~1.4 cm/year), and ~55% of tibial growth arises from the proximal physis (~1 cm/year) until skeletal maturity. Growth ceases by ~16 years in boys and ~14 years in girls. The multiplier method is also very frequently used to predict limb length discrepancies at the end of growth [9].

For example, a 10-year-old boy with osteosarcoma of the distal femur, losing the distal femoral physis after resection, will lose  $\sim 1.4 \text{ cm/year} \times 6 \text{ years} = 8.4 \text{ cm}$ . As the proximal tibia growth plates are also resected in most rotationplasty indications, an additional loss of 6 cm is expected. Surgical planning should, therefore, anticipate ~14.4 cm of overlength to achieve an equal knee joint line (of the affected rotationplasty leg and contralateral knee) and to equalize pelvic level at the end of growth [4, 10]. Relative distal tibia epiphysis overgrowth of about 2 cm compared to the contralateral side is to be expected after rotationplasty. Preoperative templating should aim to align contralateral trochanter–patella and trochanter–heel distances.



**Figure 2.**  
Templating example for preoperative planning of rotationplasty.

The multiplier table can be used to calculate the expected leg length of the contralateral leg. In this example of a 10-year-old boy, the right femur is measured at 35.8 cm. At the end of growth, the femur is expected to be  $35.8 \times 1.310$  (multiplier for a 10-year-old boy) = 46.9 cm. Taking into account the growth of the proximal femur and distal tibia, the sufficient leg length can be calculated. The height of the foot is generally 7 cm at the end of growth. Growth can also be arrested by epiphysiodesis of the growth plate to optimize leg length and symmetrical knee height. In the schematic drawing, an example of leg length measurements is shown.

## **4. Operative techniques**

### **4.1 Surgical preparation**

- **Anesthesia:** General anesthesia with a central line (or port-a-cath), arterial line, epidural analgesia catheter, and indwelling catheter (IDC).
- **Positioning:** Supine with a slight lateral tilt; consider placing the patient on a beanbag. Ensure there is adequate positioning and space for the image intensifier.
- **Antibiotic prophylaxis:** According to local protocols; we use intravenous cefazolin at induction and repeat it after 4 hours.
- Consider the use of intravenous tranexamic acid if there are no contraindications.
- **Skin marking:** Mark the preplanned osteotomy levels. Mark a circular incision at the preplanned level distal to the tip of the greater trochanter (GT). Mark a wavy incision at the knee joint to allow correction of the discrepancy in the circumference of the upper and lower legs. Finally, mark rotational alignment lines on the anterior and posterior sides of the upper and lower leg.
- **Sterile prepping and draping:** Colorless chlorhexidine for the entire limb, including the foot. Place the foot in a transparent foot bag for vascular evaluation during surgery. Apply sterile draping.

### **4.2 Rotationplasty procedures**

#### *4.2.1 Winkelmann A1 (distal femur resection)*

##### *4.2.1.1 Step 1 – Distal approach*

- Wavy incision just above the knee to correct the discrepancy in circumference between the upper and lower leg. Incise the skin 1–2 cm more proximal than the tibial plateau, allowing for some additional skin for tension-free closure. Avoid incising the skin directly over the tibial tuberosity, as this area is at higher risk for wound healing problems.

- Further dissection circumferentially around the knee with diathermy effectively simulates a knee disarticulation. Preserve the length of the patellar tendon, lateral collateral ligament (LCL), and medial collateral ligament (MCL) for later reattachment.
- In the case of intra-articular tumor growth, an extra-articular resection can be performed, leaving the joint capsule closed.
- Identification of the biceps femoris tendon laterally. Opening of the peroneal and tibial compartments. Identifying the common peroneal nerve (CPN) and mobilizing it. Following the CPN proximally, subsequently identifying and mobilizing the tibial and sciatic nerves.
- Following the tibial nerve, the medial and lateral gastrocnemius heads are divided at the musculotendinous junction.
- Identify and dissect the distal popliteal artery and vein. In cases of vascular encasement or involvement, the artery and vein can be divided, and primary anastomoses of the popliteal and femoral arteries and veins can be performed, usually by vascular or plastic surgeons. In cases of free neurovascular structures and young, small children, the artery and vein can be preserved over their entire length, rolled up (without kinking), and stored in the adductor space.
- At this point, the knee is now nearly free: nerves (sciatic, tibial, peroneal) and popliteal vessels are mobilized; cruciate ligaments are still intact.

#### *4.2.1.2 Step 2 – Medial thigh approach*

- Longitudinal medial incision from the distal to the proximal incisions.
- Identify and mobilize the great saphenous vein (GSV) over its entire course. Preserving the GSV helps with venous outflow and reduces postoperative swelling, wound problems, and blister formation, as most of the other smaller (intramuscular) venous structures are divided. Depending on its diameter, one may choose between a primary anastomosis or rolling it up.

#### *4.2.1.3 Step 3 – Posterior thigh approach*

- Longitudinal posterior incision from the distal to the proximal incisions, with further dissection using diathermy down to the fascia.
- Subsequently, develop the muscular interval, identify the sciatic nerve, and mobilize it completely toward the proximal direction.

#### *4.2.1.4 Step 4 – Proximal approach*

- Circular incision made circumferentially at the preplanned proximal osteotomy level, distal to the tip of the greater trochanter.

- Dissection with diathermy down to the fascia.
- Identification and mobilization of the superficial and deep femoral vessels.
- Identification and mobilization of the sciatic nerve.
- Separate the sartorius, gracilis, quadriceps, adductors, and hamstrings muscles with LigaSure, harmonic scalpel, or diathermy to prevent bleeding, and leave them relatively short to provide space for the NV bundle.
- At this point, both the femur and the knee are completely mobilized circumferentially.

#### *4.2.1.5 Step 5 – Osteotomies*

- Perform the femoral osteotomy at the preplanned level distal to the greater trochanter, after elevating the periosteum, with an oscillating saw.
- Perform the tibial osteotomy just distal to the growth plate. The fibular head may be left in place but is often shortened.
- Occasionally, in very young children, preservation of the proximal tibia growth plate can be preferred. Remove the articular cartilage down to the subchondral bone, and K-wire fixation may be preferred over plate fixation to allow easy removal after bone healing, thereby preserving its growth potential.
- Resect the proximal fibular epiphysis to prevent regrowth, while carefully protecting the common peroneal nerve.
- Partially resect the medial tibial plateau with an oscillating saw to a flush level with the tibial shaft.
- Dissect the soft tissue cuff circumferentially around the medial and lateral tibial plateaus.
- Separate the remaining soft tissue attachments (ACL and PCL, if not an extra-articular resection).
- Resect the distal femur and knee as one specimen, and send it for histopathology.

#### *4.2.1.6 Step 6 – Rotation and fixation*

- Rotate the lower leg 180 degrees and position the proximal tibia end-to-end against the proximal femur.
- When preserving the neurovascular structures over their entire length, place them carefully within the adductor space, while making sure they are not twisted.

- Fixation is now achieved using a locking plate with bicortical locking screws on each side, after careful repositioning. Confirm adequate alignment in the coronal, sagittal, and axial planes with an image intensifier.
- In case of vascular involvement, the anastomoses are performed after the fixation in a mechanically stable environment to prevent traction on the newly formed anastomoses.

#### *4.2.1.7 Step 7 – Closure*

- Perform a thorough washout with saline or sterile water.
- Take time for good hemostasis.
- Approximate the muscles of the upper leg to the fascia of the lower leg using loose, interrupted Vicryl 1 sutures. Do not use running sutures to close the fascia. Ensure there is no excessive tension from the sutured structures on the neurovascular bundles.
- Subcuticular suture with running Vicryl 2-0.
- Skin suture with either intracutaneous or running mattress Monocryl 3-0, knots tied outside the skin. A V-shaped skin incision on the larger diameter may facilitate the difference in skin diameter.
- Silicone wound dressing, followed by non-compressive dressing.

#### *4.2.2 Winkelmann A2 (proximal tibia resection)*

##### *4.2.2.1 Step 1 – Distal approach*

- Wavy incision on the leg at the preplanned level proximal to the calcaneus, to correct the discrepancy in circumference between the upper and lower leg. Allow for some additional skin proximal to the planned osteotomy for tension-free skin closure.
- Further dissection with diathermy down to the fascia, circumferentially.
- The lower leg musculature is transected and tagged with Vicryl 1 stay sutures.
- Incise the periosteum at the preplanned osteotomy levels for the tibia and fibula.

##### *4.2.2.2 Step 2 – Lateral approach*

- Lateral incision over the femoral and fibular sides of the upper and lower leg.
- Identification of the biceps femoris tendon laterally. Opening of the peroneal and tibial compartments. Identifying the common peroneal nerve (CPN) and mobilizing it. Following the CPN proximally, subsequently identifying and mobilizing the tibial and sciatic nerves.

- Transection of the lateral gastrocnemius (with LigaSure).
- Identify and dissect the distal popliteal artery and vein.
- Via this lateral approach to the lower leg from the trifurcation, the fibular artery and vein, anterior tibial artery and vein, and posterior tibial artery and vein are identified and dissected distally, including the course of the tibial and deep peroneal nerves. To facilitate the dissection of the neurovascular bundles, the fibula may be removed if the tumor location and margins allow.
- When the anterior tibial artery runs too close to the tumor, according to preoperative planning, it can be ligated.
- Anastomosis of these vessels onto the popliteal artery is reported with a high risk of thrombosis due to the hourglass turbulence effect caused by the difference in diameter of these vessels and should, therefore, be avoided.
- The saphenous, sural, and superficial peroneal nerves are transected.

#### *4.2.2.3 Step 3 – Posterior thigh approach*

- Extend the lateral skin incision toward until reaching the preplanned proximal circular incision. Further dissection is performed with diathermy down to the fascia.
- Subsequently, develop the muscular interval, identify the sciatic nerve, and mobilize it completely toward the proximal direction.

#### *4.2.2.4 Step 4 – Proximal approach*

- Circular incision circumferentially at the preplanned osteotomy level, distal to the tip of the greater trochanter.
- Dissection with diathermy down to the fascia.
- Identification and mobilization of the superficial and deep femoral vessels.
- Separate the quadriceps, adductors, and hamstrings muscles using LigaSure, harmonic scalpel, or diathermy to prevent bleeding.
- At this point, both the femur and tibia are completely mobilized circumferentially.

#### *4.2.2.5 Step 5 – Osteotomies*

- Perform the femoral osteotomy at the preplanned level (providing the planned length of the rotationplasty), after elevating the periosteum with an oscillating saw.

- Perform the tibial and fibular osteotomies at the preplanned level proximal to the ankle joint, guided by sufficient margins and the planned length of the rotationplasty.
- Resect the proximal tibia and knee as one specimen, and send it for histopathology.

#### *4.2.2.6 Step 6 – Rotation and fixation*

- Using the preoperative skin markings on the tibia and femur, rotate the lower leg 180 degrees and position the distal tibia end-to-end against the proximal femur.
- Fixation is now achieved using a locking plate with bicortical locking screws on each side, after careful repositioning. Confirm adequate alignment in the coronal, sagittal, and axial planes with an image intensifier. If growth from the distal femoral physis is needed and anticipated, the tibia can be fixed using K-wires.
- Create space for the vessels within the hamstring compartment.

#### *4.2.2.7 Step 7 – Closure*

- Perform a thorough washout with saline or sterile water.
- Take time for good hemostasis.
- Suture the quadriceps muscle fascia to the (long) preserved gastrocnemius flap or Achilles tendon, depending on the level of the resection, with Vicryl.
- Suture the tibialis anterior tendon (TA), extensor hallucis longus (EHL), and extensor digitorum longus (EDC) to the hamstrings (semimembranosus, semitendinosus) and biceps femoris with Vicryl 1.
- Do not use running sutures to close the fascia. Make sure there is not too much tension on the sutured structures.
- Subcuticular suture with running Vicryl 2-0.
- Skin sutures with either intracutaneous or running mattress Monocryl 3-0, with knots tied outside the skin.
- Silicone wound dressing, followed by non-compressive dressing.

#### *4.2.3 Winkelmann B3 (total femur resection)*

##### *4.2.3.1 Step 1 – Distal approach*

- Wavy or U-shaped incision just above the knee to correct the discrepancy in circumference between the upper and lower leg. Incise the skin 1–2 cm more proximal than the tibial plateau, allowing for some additional skin for

tension-free closure. Avoid incising the skin directly over the tibial tuberosity, as this area is at higher risk for wound healing problems. In selected cases, the anterior fascio-cutaneous skin flap overlying the quadriceps is preserved to facilitate skin closure over the gluteal musculature after rotation.

- Further dissection circumferentially around the knee with diathermy effectively simulates a knee disarticulation. Preserve the length of the patellar tendon, the circumferential capsule, including LCL and MCL, for later reattachment. Preserve the ACL for later attachment to the ligamentum teres.
- Identification of the biceps femoris tendon laterally. Opening of the peroneal and tibial compartments. Identifying the common peroneal nerve (CPN) and mobilizing it. Following the CPN proximally, subsequently identifying and mobilizing the tibial and sciatic nerves.
- Following the tibial nerve, the medial and lateral gastrocnemius heads are divided at the musculotendinous junction.
- Identify and dissect the distal popliteal artery and vein. In case of vascular encasement or involvement, the artery and vein can be divided, and primary anastomoses of the popliteal and femoral arteries and veins can be performed, usually by vascular or plastic surgeons. In the case of free neurovascular structures and young and small children, the artery and vein can be preserved over their entire length, rolled up (without kinking), and stored in the adductor space.
- At this point, the knee is now nearly free: nerves (sciatic, tibial, peroneal) and popliteal vessels are mobilized; cruciate ligaments are still intact.
- The deep femoral vein is ligated and transected posteriorly from the knee to facilitate anastomosis to the great saphenous vein (GSV), if the GSV cannot be reconstructed or left intact.

#### *4.2.3.2 Step 2 – Medial thigh approach*

- Longitudinal medial incision from the distal to the proximal incision.
- Identify and mobilize the GSV over its entire course. Preserving the GSV helps with venous outflow and reduces postoperative swelling, wound problems, and blister formation, as most of the other smaller (intramuscular) venous structures are divided. Depending on its diameter, one may choose between a primary anastomosis and rolling up.
- Identify the superficial femoral artery and vein, and dissect or transect them, leaving as long as the margins allow.

#### *4.2.3.3 Step 3 – Posterior thigh approach*

- Longitudinal posterior incision from the distal to the proximal incisions, with further dissection using diathermy down to the fascia.

- Subsequently, develop the muscular interval and identify the sciatic nerve, and mobilize this completely toward proximally.

#### *4.2.3.4 Step 4 – Proximal approach*

- Circular incision circumferentially at the groin level, from the anterior superior iliac spine (ASIS) through the gluteal crease.
- Dissection with diathermy down to the fascia.
- Identification and mobilization of the superficial and deep femoral vessels.
- Sartorius released from ASIS, rectus femoris from anterior inferior iliac spine (AIIS), adductors/pectineus from the superior pubic ramus.
- Gluteus maximus and tensor fascia lata insertions divided.
- Anterior hip capsule exposed; gluteus medius released from the greater trochanter.
- Iliopsoas divided at the lesser trochanter if margins allow.
- Identification and mobilization of the sciatic nerve.
- Proceed proximally by releasing the sartorius, rectus femoris, adductors, gluteal insertions, and iliopsoas while dissecting the femoral nerve and iliac vessels.
- Open the hip joint, divide the capsule and ligamentum teres, and remove the femur en bloc with associated lymph nodes.
- If margins allow, transect the hip capsule around the femoral neck.
- At this point, both the femur and knee are completely mobilized circumferentially. Resect the total femur/thigh as one specimen and send it for histopathology.

#### *4.2.3.5 Step 5 – Rotation and fixation*

For Winkelmann B3 rotationplasties, in which the entire femur and thigh are removed because of extensive femoral tumor involvement, there are two options for reconstruction.

#### *4.2.3.6 Winkelmann B3A*

*In the youngest children below the age of five, there is good remodeling capacity of the lateral tibial plateau to a neo-femoral head when placed inside the acetabulum.*

- Start with the preparation of the tibial plateau. Mobilize the soft tissue cuff of the lateral tibial plateau. The lateral meniscus can be left on the capsule or excised. Protect the articular cartilage of the lateral tibial plateau.
- The fibular head is dissected and removed; the course of the common peroneal nerve should be carefully preserved.
- The lower leg can now be rotated, and the lateral tibial plateau seated into the acetabulum.
- Soft tissue reconstructions:
  - ACL attached to the ligamentum teres.
  - MCL attached to the lateral labrum.
  - Medial capsule is attached to the lateral labrum.
  - Lateral gastrocnemius head fixation with transosseous sutures to the superior pubic ramus, if length allows.
  - Medial gastrocnemius head fixation to the cranial labrum, just below the rectus femoris origin.
  - Gluteal and psoas musculature is reinserted onto the tibial capsule.

#### *4.2.3.7 Winkelmann B3B*

*In older children and adolescents, the remodeling capacity is lacking due to their advanced growth, and cementing a hip hemiarthroplasty in the tibia should be considered. Preoperative templating is crucial for determining the correct size of the implant and head.*

- Start with the preparation of the tibial plateau. Mobilize the soft tissue cuff of the lateral tibial plateau. Remove the lateral meniscus.
- The fibular head is dissected and removed; the course of the common peroneal nerve should be carefully preserved.
- Prepare the tibia for the cemented hemiarthroplasty. It is advisable to use a modular implant with a straight stem to allow for the correction of rotation once the stem is cemented in place.
- Ream to the correct stem diameter. Place a cement restrictor in the tibial stem. Cement the definitive modular stem into the tibial shaft.
- Place the body of the prosthesis with the trunnion in the correct rotation, and place the ceramic head (preoperatively template the size to match the acetabulum).

- The lower leg can now be rotated, and the hemiarthroplasty reduced into the acetabulum.
- Soft tissue reconstructions:
  - MCL attached to the lateral labrum.
  - Medial capsule attached to the lateral labrum.
  - Lateral gastrocnemius head fixation with transosseous sutures to the superior pubic ramus, if length allows.
  - Medial gastrocnemius head fixation to the cranial labrum, just below the rectus femoris origin.
  - Gluteal and psoas musculature is reinserted onto the tibial capsule.
- In the case of vascular anastomoses, check for stability and rotation, as this may still be adjusted.

#### *4.2.3.8 Step 6 – Vascular anastomoses (if needed)*

- Typically, end-to-end anastomoses of the external iliac artery and vein to the popliteal artery and vein are performed by plastic or vascular surgeons (separate operation notes are available from the authors upon request).
- Additionally, the deep femoral vein and great saphenous vein can be anastomosed end-to-end to allow for adequate venous outflow of the lower leg.

#### *4.2.3.9 Step 7 Closure*

- Perform a thorough washout with saline or sterile water.
- Take time for good hemostasis.
- Suture the fascia of the lower leg to the fascia of the abdominal wall with interrupted Vicryl 1. Do not use running sutures to close the fascia to prevent vascular or neurological compression as a result of postsurgical swelling. Make sure there is not too much tension on the sutured structures.
- Subcuticular suture with running Vicryl 2-0.
- Skin sutures with either intracutaneous or running mattress Monocryl 3-0, with knots tied outside the skin.
- Silicone wound dressing, followed by non-compressive dressing.

## **5. Postoperative care and rehabilitation**

### **5.1 Direct postoperative care**

- Monitoring of capillary refill every hour for the first 24 hours. If not possible on a normal surgical ward, overnight ICU admission is advised.
- DVT prophylaxis, when indicated.
- Pain control: epidural analgesia catheter and IDC after checking neurological status; referral to the pain team.
- Positioning: foot elevated on a pillow, toes free from the mattress, to prevent decubitus and pressure sores whilst the epidural analgesia catheter is *in situ*.
- Antibiotics: as per local protocols; we continue cefazolin for 24 hours (3× daily, weight-adjusted).
- Imaging: postoperative conventional radiographs of the hip and lower limb.
- Wound: remove non-compressive dressing after 24–48 hours; leave silicone dressing on for 7 days or until wound inspection.
- Mobilization: directly start foot and ankle exercises to prevent postoperative swelling and reduce stiffness. Maintain bed rest while the epidural analgesia catheter is in place; once removed, begin non-weight-bearing mobilization under the supervision of physiotherapy. Early verticalization prevents contractures.

### **5.2 Rehabilitation and prosthetic management**

- Days 1–3: Active toe and ankle mobilization.
- Days 4–7: Non-weight-bearing exercises and walking with a frame or two crutches.
- After three to four weeks: Temporary prosthesis fitting.
- After three to six months: Progressive gait training and sports reintroduction following bone healing.
- Final prosthesis: designed in ankle dorsiflexion to allow “full extension” in stance. Definitive sockets are fitted after union, typically without ischial tuberosity support.
- Patients benefit from energy-storing prostheses; gait analyses show lower energy expenditure compared to transfemoral amputees.
- Rehabilitation focuses on gait re-education, proprioception, and sports participation [4, 11, 12].

## **6. Complications**

Early complications:

- Arterial occlusion and compromised venous outflow. Vessel-sparing techniques reduce the risks of problems with venous return; venous torsion must be avoided.
- Venous thrombosis (<1%)
- Infection: rare, but can lead to serious complications, requiring aggressive debridement.
- Wound healing problems may require surgical wound revision but can mostly be managed with vacuum-assisted closure (VAC) dressings.

Late complications:

- Nonunion: minimized by compression-stable fixation (<1%).
- Malrotation: requires corrective osteotomy if symptomatic.
- Fracture: especially tibial shaft, is mostly managed conservatively.
- Contracture of the ankle or hip: prevented by early physiotherapy and verticalization.
- Diffuse ankle osteopenia is common, but clinically significant arthritis is rare [4,5].

## **7. Functional outcomes, quality of life, and oncologic safety**

### **7.1 Function and quality of life**

Studies consistently show good-to-excellent long-term functional outcomes, including excellent participation in daily life activities and sports participation, such as high-impact and contact sports. Long-term series (>20 years) show MSTTS scores >80% and LEFS within the normal range for age.

Compared with transfemoral amputation, rotationplasty has lower energy expenditure, better gait symmetry, and no phantom pain.

Quality of life is comparable to, or better than, amputation or endoprostheses [12–14]. The rate of sports participation (running, soccer, skiing) is high in rotationplasty.

### **7.2 Psychosocial impact**

Psychosocial adaptation is favorable when adequate preoperative counseling is provided [2, 15]. Physical appearance and the esthetic concerns about rotationplasty are the main hurdles. With preoperative counseling, greater than 85% of patients and

parents report satisfaction with function and lifestyle. Given the profound impact of procedures like rotationplasty, shared decision-making (SDM) is essential to ensure that patients and parents are fully informed and actively involved in choosing the most suitable treatment. This will contribute to patient-centered care and will increasingly empower patients and families in choosing their preferred reconstructive option.

Oncologic margins and survival are not compromised; outcomes reflect tumor biology and systemic therapy [16]. Follow-up studies over 30 years show durability without the revision burden typical of megaprotheses [17].

## **8. Practical pearls and checklist**

### **8.1 Preoperative tips**

- Multidisciplinary planning, including psychosocial counseling.
- Templating for predicted growth and length at skeletal maturity.
- In general, perpendicular osteotomies are preferred.
- For Winkelmann A1, generally aim for a relatively high osteotomy of the femur, about 5–7 cm below the trochanter minor or more distally if the femur is placed into the proximal tibia, to prevent a long rotationplasty at the end of growth.
- For Winkelmann A2, the femoral side is osteotomized depending on the resection length of the tibia.
- For Winkelmann B3b: template the modular hemiarthroplasty.

### **8.2 Intraoperative tips**

- Skin marking, including orientation lines on the anterior and posterior sides of the thigh and lower leg, for orientation after rotation.
- Use a wavy incision distally for better skin closure.
- Protect venous drainage by preserving perforators and saving the great saphenous vein if possible.
- Confirm vascular pedicle orientation and preserve at least two out of three lower leg vessels.
- To identify the common peroneal nerve: open the fascia of the peroneus longus muscle, then cut fiber by fiber until the common peroneal nerve is exposed and can be freed.
- Laterally identify the common peroneal nerve, follow it to the sciatic nerve, and from there, find the tibial nerve.

- Early dissection of the lateral gastrocnemius significantly improves exposure to the neurovascular bundle.
- Perform the osteotomy below the proximal tibial growth plate to prevent tethered growth, resulting in a valgus of the leg.
- The fibula can be left intact or shortened to allow for a better fit and to correct size differences; perform epiphysiodesis if necessary.
- Verify kinematics and alignment, including rotation, before final fixation. Temporary short K-wires can be placed in the femur and tibia to test that dorsiflexion equals knee flexion and to assess rotation and angulation.
- Avoid under- or over-rotation, as it impairs gait or venous return.
- Fixation with lateral AO locking compression plate (LCP), small fragment for younger children, and large fragment for older children and adolescents.
- Fix the plate onto the lateral side of the femur first to add extra stability, allowing for easier medial fixation of the plate onto the tibia.
- Osteotomy of the medial side of the tibia to allow for the use of a straight plate and fixation under compression.
- For Winkelmann B3b: Check for rotation of the hip after temporary first fixation, as the modular implant can still be adjusted at this time.
- Before closing the fascia, photograph the location of the neurovascular bundle for future reference, in case of the need for reoperations.

### **8.3 Postoperative tips**

- Directly postoperatively, perform a full neurovascular check before a complete motor block occurs due to the epidural.
- Hourly capillary refill and vascular checks; consider ICU monitoring if not available on the surgical ward.
- Elevation of the limb helps prevent swelling and promotes venous return.
- For faster recovery, start early range of motion exercises with ongoing physiotherapy to reduce swelling and progressive prosthetic fitting [4, 7].

## **9. Conclusion**

Rotationplasty provides a durable, growth-compatible, and highly functional reconstructive option for children and young adults who require resection of malignant bone tumors around the knee. While cosmetic appearance remains

challenging, oncologic safety, functional outcomes, and long-term patient satisfaction are consistently excellent. With proper patient selection, good preoperative counseling, meticulous surgical technique, and structured rehabilitation, rotationplasty remains one of the most successful biological reconstructions in pediatric orthopedic oncology, especially when durable function and quality of life are prioritized.


### **Author details**

Lizz van der Heijden, Jonneke Kuperus and Michiel van de Sande\*  
Orthopedics, Princess Máxima Center, Utrecht, Netherlands

\*Address all correspondence to: [michielvds@me.com](mailto:michielvds@me.com)

### **IntechOpen**

---

© 2025 The Author(s). Licensee IntechOpen. This chapter is distributed under the terms of the Creative Commons Attribution License (<http://creativecommons.org/licenses/by/4.0/>), which permits unrestricted use, distribution, and reproduction in any medium, provided the original work is properly cited. 

## References

- [1] Bernthal NM, Monument MJ, Randall RL, Jones KB. Rotationplasty: Beauty is in the eye of the beholder. *Operative Techniques in Orthopaedics*. 2014;**24**:103–110
- [2] Sawamura C, Hornicek FJ, Gebhardt MC. Complications and risk factors for failure of rotationplasty: review of 25 patients. *Clinical Orthopaedics and Related Research*. 2008;**466**:1302–1308
- [3] Catani F, Capanna R, Benedetti MG, et al. Gait analysis in patients after Van Nes rotationplasty. *Clinical Orthopaedics and Related Research*. 1993;**296**:270–277
- [4] de Sande Maj V, Vochteloo AJH, Dijkstra PDS, Taminiau AHM. Van Nes-Borggreve Rotationplasty of the Knee. In Bentley G, editor. *European Surgical Orthopaedics and Traumatology*. Berlin: Springer; 2014. p. 4135–4147
- [5] Krebbekx GGJ, Smithuis FF, Duivenvoorden MJC, et al. Good long-term functional outcomes after rotationplasty despite osteoarthritis in the (pseudo)knee. *Osteoarthritis and Cartilage Open* 2025;**7**:100644
- [6] Fuller CB, Lichtblau CH, Paley D. Rotationplasty for Severe Congenital Femoral Deficiency. *Children (Basel, Switzerland)*. 2021;**8**(6):462
- [7] Gottsauner-Wolf F, Kotz R, Knahr K, Kristen H, Ritschl P, Salzer M. Rotationplasty for limb salvage in the treatment of malignant tumors at the knee. A follow-up study of seventy patients. *The Journal of Bone & Joint Surgery*. 1991;**73**:1365–1375
- [8] Cammisa Jr FP, Glasser DB, Otis JC, Kroll MA, Lane JM, Healey JH. The Van Nes tibial rotationplasty. A functionally viable reconstructive procedure in children who have a tumor of the distal end of the femur. *The Journal of Bone and Joint Surgery. American Volume*. 1990;**72**:1541–1547
- [9] Paley D, Bhave A, Herzenberg JE, et al. Multiplier method for predicting limb-length discrepancy. *The Journal of Bone and Joint Surgery-American Volume* 2000;**82**:1432–1446
- [10] Anderson M, Green WT, Messner MB. Growth and predictions of growth in the lower extremities. *The Journal of Bone & Joint Surgery*. 1963;**45**:1–14
- [11] Hillmann A, Rosenbaum D, Schroter J, Gosheger G, Hoffmann C, Winkelmann W. Electromyographic and gait analysis of forty-three patients after rotationplasty. *The Journal of Bone and Joint Surgery-American Volume*. 2000;**82**:187–196
- [12] Gradl G, Postl LK, Lenze U, Stolberg-Stolberg J, Pohlig F, Rechl H, Schmitt-Sody M, von Eisenhart-rothe R, Kirchhoff C, et al. Long-term functional outcome and quality of life following rotationplasty for treatment of malignant tumors. *BMC Musculoskeletal Disorders*. 2015;**16**:262
- [13] Rödl RW, Pohlmann U, Gosheger G, Lindner NJ, Winkelmann W. Rotationplasty–quality of life after 10 years in 22 patients. *Acta Orthopaedica Scandinavica*. 2002;**73**:85–88
- [14] Tigelaar LG, Haveman LM, Bekkering WP, et al. A multidisciplinary

and structured approach for comprehensive evaluation of functional outcomes, adverse events, psychosocial outcomes and health-related quality of life after local therapy for bone sarcoma in children: Protocol for a cross-sectional study. *Frontiers in Pediatrics* 2025; **45**:1534153

[15] van der Hoek H, Tigelaar LG, Maurice-Stam H, et al. Body image of patients in follow-up for pediatric bone sarcoma: Implications of tumor location and local therapy. *Journal of Cancer Survivorship*. 2025. DOI: 10.1007/s11764-025-01847-9

[16] Barr RD, Wunder JS. Bone and soft tissue sarcomas are often curable—But at what cost? *Cancer*. 2009; **115**:4046–4054

[17] Windhager R, Dominkus M, Krepler P, et al. Rotationplasty for malignant tumors of the proximal femur. *The Journal of Bone and Joint Surgery. American Volume*. 1996; **78**:593–602