

Management of Skeletal Metastases

Patient Data

Physician: **John Smith**

Patient's name (Initials): **IM**

Age: **74**

Sex: **F**

Histological diagnosis: **Carcinoma of breast**

Anatomical location:

(please mark side, location, and exact anatomical extent of the lesion)

Solitary metastasis: Yes No

Visceral metastases: Yes, Site: No

Presentation:

Pathological fracture

Impending fracture

Painful lesion

Matrix:

Blastic

Lytic

Mixed

Associated pain:

Mild

Moderate

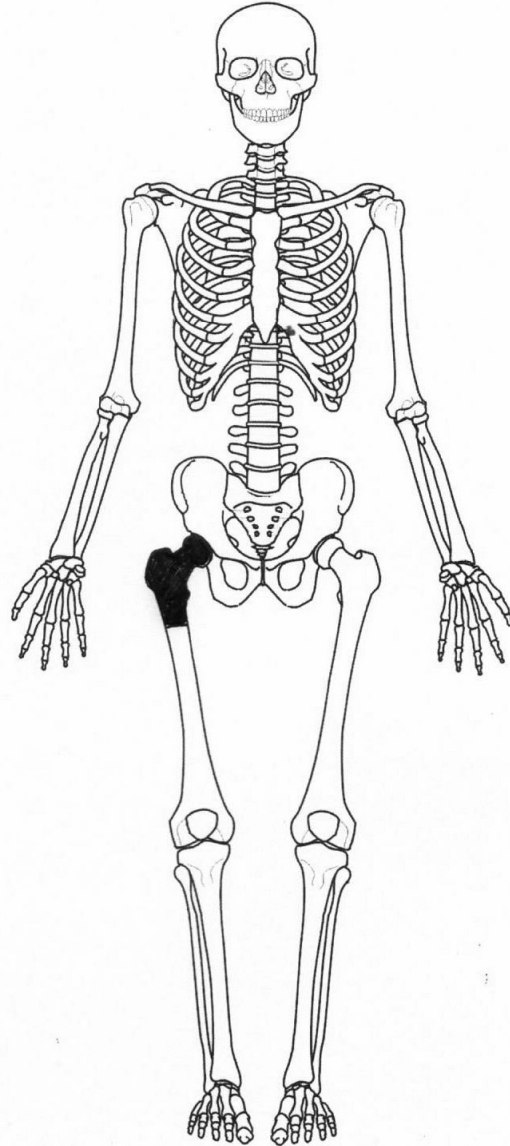
Functional (Aggravated by function)

Extent of bone diameter involvement:

<1/3

1/3 - 2/3

>2/3



Prior treatment:

Chemotherapy: Yes, No

Bisphosphonates: Yes, No

Radiation: Yes, No

Previous surgery: Yes, No

Other:

Surgery: Yes, No

1. Intramedullary rodding - open, closed, with PMMA, without PMMA

2. Plating - with PMMA, without PMMA

3. Resection with prosthetic reconstruction

4. Minimally invasive percutaneous surgical procedure.

Type: _____

5. Amputation

6. Other: _____

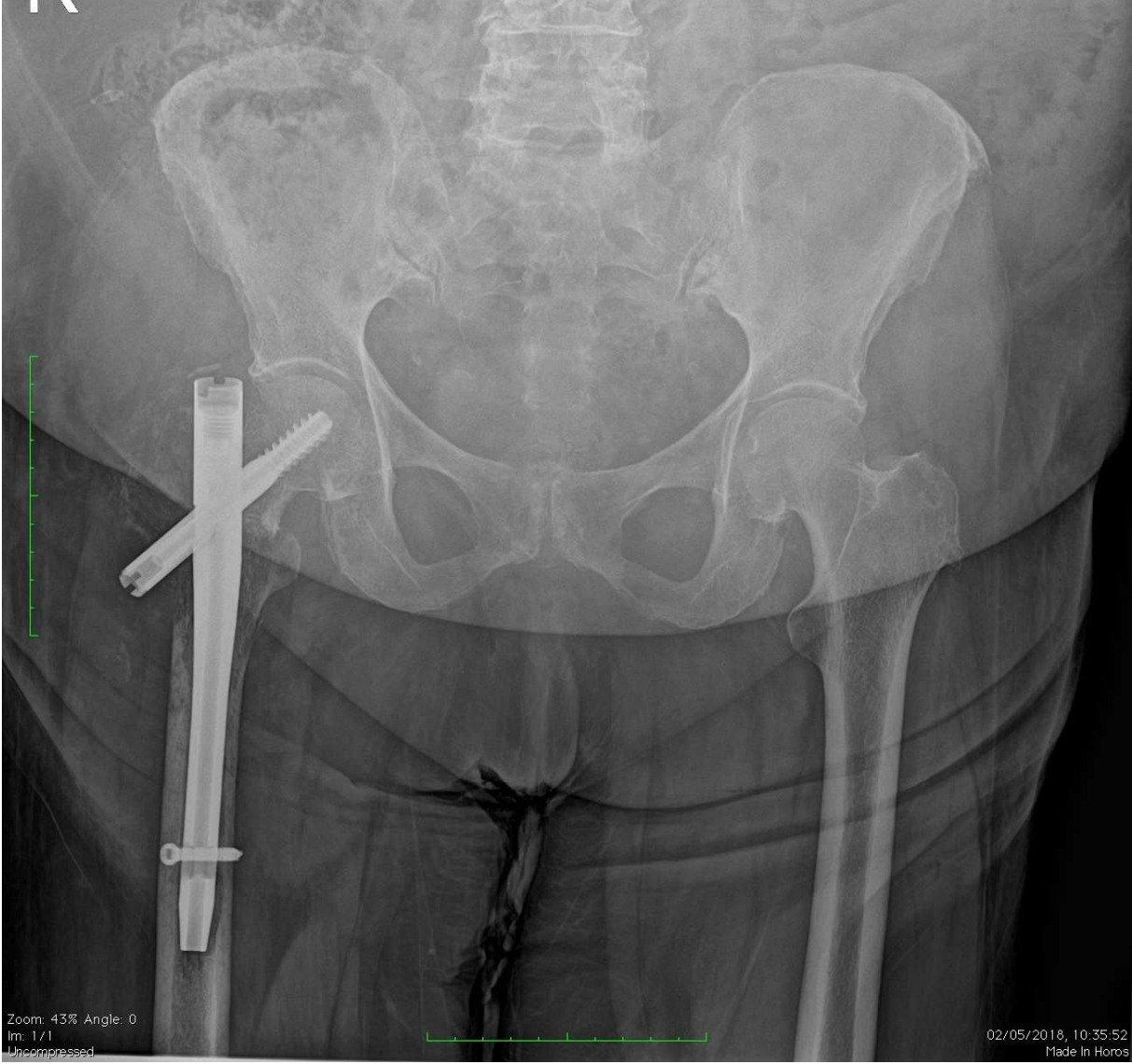Post-operative radiation: Yes, No

Comments: _____

Image size: 5055 x 3059
View size: 1300 x 1302
WL: 3192 WW: 16337

6880334 (78 y , 78 v)
Xr Pelvis - Hip (S)
PELVIS AP
1

R



Zoom: 43% Angle: 0
Im: 1/1
Uncompressed

02/05/2018, 10:35:52
Made In Horos